

UDC 616-001.4:576.31+615.281-085:616.42

**PHARMACOKINETIC PARALLELS OF GENTAMICIN IN BLOOD,
LYMPH NODES AND SOFT TISSUES OF A GUNSHOT WOUND TO
AN EXTREMITY BY DIFFERENT METHODS OF ADMINISTRATION.**

Mirzayev Kamal Karimovich

assistant professor, Andijan state medical institute.

Andijan ,Uzbekistan.

Mirzayev Kamal Karimovich: :

<https://orcid.org/0000-0002-4682-9119>

Summary

This article presents the positive results of experimental experiments performed on rabbits. These experiments were performed on experimental animals - rabbits to study the pharmacokinetics of the antibiotic - gentamicin, with various methods of its administration, against the background of inflicting a gunshot wound on the rabbit's limb. The results of the studies showed that a high and long-lasting content of gentamicin in the lymph nodes and in the tissues of the gunshot wound area occurred with the lymphotropic method of its administration.

Key words: discovery of damage, lymphotropic therapy, pharmacokinetics of antibiotics.

УДК 616-001.4:576.31+615.281-085:616.42

**ФАРМАКОКИНЕТИЧЕСКИЕ ПАРАЛЛЕЛИ ГЕНТАМИЦИНА В
КРОВИ, ЛИМФАТИЧЕСКИХ УЗЛАХ И МЯГКИХ ТКАНЯХ
ОГНЕСТРЕЛЬНОЙ РАНЫ КОНЕЧНОСТИ ПРИ РАЗЛИЧНЫХ
МЕТОДАХ ВВЕДЕНИЯ.**

Мирзаев Камал Каримович

к.м.н., доцент Андижанский государственный медицинский институт.

Андижан, Узбекистан

Резюме

В настоящей статье приведены положительные результаты выполненных экспериментальных опытов на кроликах. Эти эксперименты были выполнены на подопытных животных – кроликах по изучению фармакокинетики антибиотика - гентамицина, при различных способах его введения, на фоне нанесения огнестрельной раны конечности кролика. Результаты исследований показали, что высокое и длительно удерживающееся содержание гентамицина в лимфатических узлах и в тканях области огнестрельной раны имела места при лимфотропном способе его введения.

Ключевые слова: открытие повреждения, лимфотропная терапия, фармакокинетика антибиотиков.

УДК 616-001.4:576.31+615.281-085:616.42

**EKSPERIMENTDA O'QOTAR QUOLLARDAN OLINGAN
JAROXATLARDAN SO'NG, GENTAMITSINNI QONDA, LIMFATIK
TUGUNLARDA VA YUMSHOQ TO'QIMALARDA
FARMAKOKINETIK PARALLELLARI.**

t.f.n. docent, Mirzayev Kamal Karimovich Andijan Davlat Tibbiyot Instituti

Andijan Uzbekistan

REZYUME

Mazkur maqolada quyonlarda bajarilgan eksperimental ishlarning ijobiy natijalari keltirilgan. Bunda oyoqda o'qotar quoldan jarohat hosil qilingan 40 ta tajribaosti quyonlarida gentamitsin antibiotikining farmakokinetikasi o'rganildi. O'qotar qurol yordamida chaqirilgan jarohatni bartaraf etishda antibiotiklardan - gentamitsin turli usullarda tajriba osti hayvoniga yuborildi. Tekshiruv natijalari shuni ko'rsatdiki, limfotrop usulda qo'llanilgan antibiotikoterapiyada gentamitsinning uzoq vaqt davomida yuqori miqdorda qonda, limfa tugunlarida va yumshok to'qimalarda bo'lishi isbotlandi.

Kalit so'zlar: ochiq jarohat, limfotrop terapiya, antibiotiklarning farmakokinetikasi.

ABSTRACT

The widespread use of firearms with high kinetic energy in local military conflicts has led to an increase in the number of severe wounds to the extremities, characterized by significant damage to soft tissues, blood vessels and multiple fractures [4,6,10]. In the course of providing modern medical care to the wounded in Afghanistan and the Chechen Republic, it was found that in 28% of cases, gunshot wounds to the extremities were complicated by purulent-infectious processes [1,11,15].

At the end of the 20th century, both in the CIS countries and in the world

as a whole, there was a sharp increase in the number of gunshot injuries among the civilian population [3,9]. Today, gunshot injury is an urgent problem not only for military medicine but also for civilian health care.

The presence of inevitable bacterial contamination and massive destruction of tissues of modern gunshot wounds leads to a large number of purulent complications, which necessitates continuous improvement of local and general treatment methods [4].

A gunshot wound due to primary contamination, the presence of wound detritus, areas of soft tissue damage usually heals by secondary intention. In the event of primary microbial contamination of the wound, "street" strains, as well as saprophytes from the skin, enter it. The predominantly lymphomatous spread of the infection leads to the formation of abscesses near the wound, phlegmon, severe wound edema, and sepsis. In this regard, the methods of endolymphatic antibiotic therapy and stimulation of lymphatic drainage are of particular relevance [7,10].

INTRODUCTION

In recent years, along with surgical methods, a number of clinics have successfully used regional lymphotropic antibiotic therapy with regional lymphatic stimulation to influence a purulent wound [2,5]. However, clear parameters, indications, and the possibility of using regional lymphotropic antibiotic therapy with regional lymphatic stimulation in a complex of therapeutic measures for gunshot wounds of the extremities have not been developed.

To date, the possibilities of regional lymphatic stimulation and lymphotropic antibiotic therapy, for gunshot wounds of the extremities, in the prevention and treatment of purulent septic complications have not been sufficiently studied. The study of the role of lymphatic stimulation and lymphotropic antibiotic therapy in the complex treatment of soft-tissue gunshot wounds seems promising in terms of combating wound edema and

microcirculation disorders. The possibility of full penetration of antibiotics into the tissues of the zone of molecular concussion, blood flow and regional lymph nodes in case of gunshot wounds is not clear. Therefore, it is necessary to carefully study the ultrastructure and pharmacokinetics of antibiotics, as well as to determine the possibilities of lymph stimulation and lymphotropic antibiotic therapy of the wound process.

The clinical efficacy of lymphotropic therapy with regional lymphatic stimulation in the treatment of gunshot wounds in the extremities requires study.

MATERIALS AND METHODS

The clinical part of the work was carried out in the Andijan branch of the RCMP on the events of the terrorist attack on May 13, 2005 in the city of Andijan. During this period, 169 victims with gunshot wounds to the extremities were analyzed.

Distribution of the wounded by gender, age, and by the nature of surgical interventions.

All patients (169) with gunshot wounds to the extremities were divided into 4 groups according to the nature of injuries and complications, each of which consisted of the main group, where the methods of lymphatic therapy were used in the complex of therapeutic measures and the control group, where the treatment was carried out by traditional methods.

Characteristics of groups of victims:

Group I. Gunshot wounds of the soft tissues of the limb (59):

Main - 40 wounded

Control - 19 wounded.

Group II. Gunshot bone fractures, without extensive defect and soft tissue damage (31):

Main - 16 wounded

Control - 15 wounded.

III group. Gunshot fractures of bones, with extensive damage to soft

tissues (42):

Main - 26 wounded

Control - 16 wounded.

IV group. Infectious complications of gunshot wounds to the extremities (37):

Main - 25 wounded

Control - 12 wounded.

Experimental research consisted of 2 stages. The first stage consisted of modeling a standard gunshot wound on the right lower limb of the rabbit according to the above-described method, as well as taking blood, removing the inguinal lymph nodes and soft tissues of the area of the gunshot wound. This part of the experiments was carried out at the Central Scientific Research Laboratory of the Andijan State Medical Institute.

The second stage consisted of determining the concentration of the antibiotic for various methods of its administration in biological fluids and tissues, as well as studying the pharmacokinetic efficacy of the lymphotropic method of antibiotic therapy. It was held in the center of genomic technologies of the Institute of Genetics and Experimental Biology of Plants of the Academy of Sciences of the Republic of Uzbekistan (leading researcher, Ph.D. G. Mavlanov).

40 rabbits of both sexes weighing 5-6 kg under Calypsol anesthesia were inflicted with a gunshot wound to the right lower extremity and a series of experiments were carried out. We used gentamicin to study the pharmacokinetics. Gentamicin was administered to animals once in an amount of 1 mg/kg, which corresponds to the average therapeutic dose for an adult.

In the first series of experiments, 10 rabbits were injected lymphotropically (LT) according to the method described above gentamicin.

In the second series (control), 10 rabbits were injected with gentamicin subcutaneously (PC) without the use of lymph stimulant.

In the third series (10 rabbits), gentamicin was injected intramuscularly (IM) into the thigh area.

In the fourth series of experiments (10 rabbits), gentamicin was injected into a peripheral vein (iv).

To determine the concentration of the antibiotic, blood serum in a volume of 1–4 ml was taken 0.5, 1, 3, 6, and 24 hours after the administration of gentamicin. After 6 hours, some of the animals after i / m (5 rabbits), i / v (5 rabbits), and s / c (5 rabbits), as well as l / t (5 rabbits) were deliberately withdrawn from the experiment by introducing increased doses of Calyptol. The other part of the animals after l / t (5 rabbits) and after s / c, i / m, i / v (5 rabbits in each of the series) methods were withdrawn from the experiment after 24 hours. This made it possible to extract the inguinal lymph nodes and pieces of soft tissue from the area of the gunshot wound within the specified time frame. The tissues were homogenized by rubbing with quartz sand. Distilled water was added to the homogenate. The resulting suspension was centrifuged for 30 min at 2500 rpm. The concentration of gentamicin was determined in the supernatant.

RESULTS AND DISCUSSION

For a more visual presentation, it is advisable to draw pharmacokinetic parallels of lymphotropic and traditional (intramuscular, intravenous, and subcutaneous) methods of gentamicin administration. Analysis of the kinetics of gentamicin in the blood for various routes of administration (Fig. 1) shows that traditional methods create a peak concentration in a period of time equal to 0.5-1 hour. Then the concentration drops rather quickly and by 6 hours from the moment of administration the level of the drug in different animals ranged from "traces" of the antibiotic to 1.6 µg / ml. Average concentration values did not reach therapeutic values. With lymphotropic administration, the highest concentration falls on a time period of 1 hour and this indicates a relatively rapid penetration of the drug in a sufficiently high concentration into the blood. In the

future, the curve (Fig. 2) is less gentle than with intramuscular and intravenous administration (Fig. 3). After 6 hours, the concentration of the antibiotic in the blood is 1.8-3.4 times higher with lymphotropic administration than in experiments with intramuscular, intravenous, and subcutaneous administration of the drug. After 24 hours, with traditional injections, gentamicin in blood was not detected in any of the animals. Lymphotropic administration, on the other hand, created gentamicin concentrations close to therapeutic ones, on average $1.07 + 0.23 \mu\text{g} / \text{ml}$. These concentrations are inhibitory for most microorganisms that are most commonly encountered in surgical practice (Figure 4)

It should be noted that the resulting subtherapeutic blood concentrations 24 hours after a single lymphotropic administration of the drug in an average therapeutic dose make it possible to conduct lymphotropic antibiotic therapy once a day.

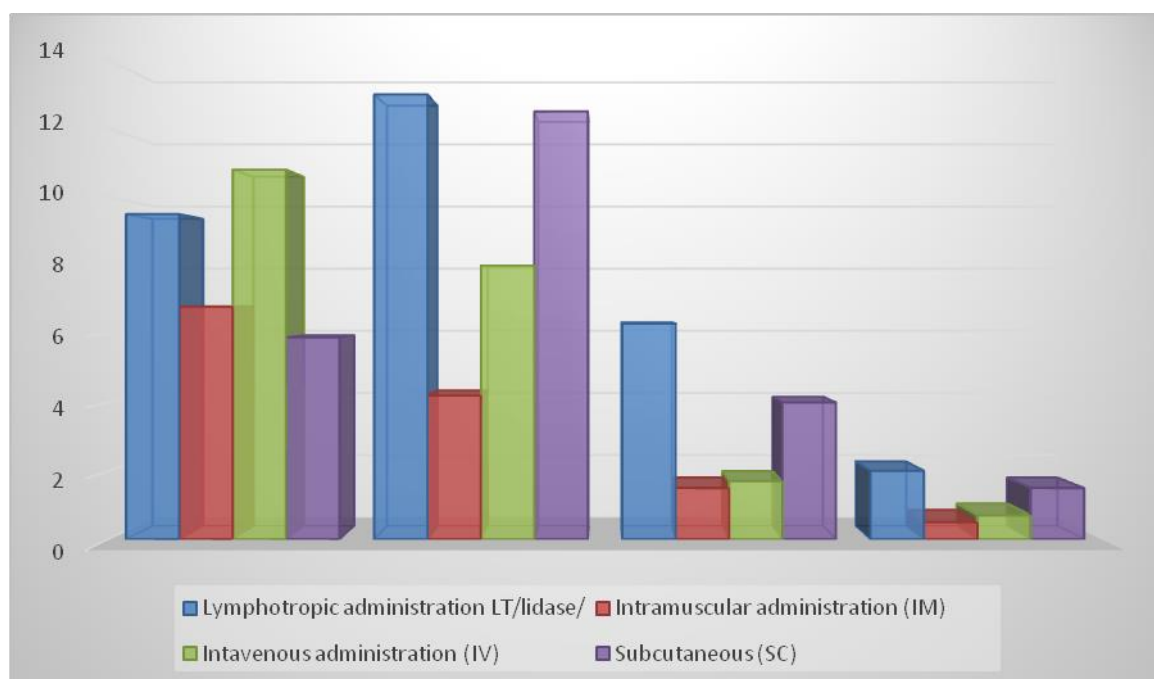


Fig. 1 Dynamics of the concentration of gentamicin in the blood after various methods of antibiotic administration at a dose of 1 mg/kg

Summarizing the data of experimental studies on the content of

gentamicin in the blood, we can say that the method of lymphotropic antibiotic therapy, when using an average therapeutic dose of an antibiotic administered once, provides more stable and long-term blood saturation compared to traditional methods.

Comparison of the content of gentamicin in the inguinal lymph nodes and soft tissues of the gunshot wound of an extremity with various methods of application showed that 6 hours after administration in the inguinal lymph nodes the highest concentration corresponding to $1.44 + 0.64 \mu\text{g} / \text{g}$ is created with the lymphotropic method (Fig. 3). With intramuscular injection after 6 hours, only "traces" of the antibiotic were noted in the inguinal lymph nodes.

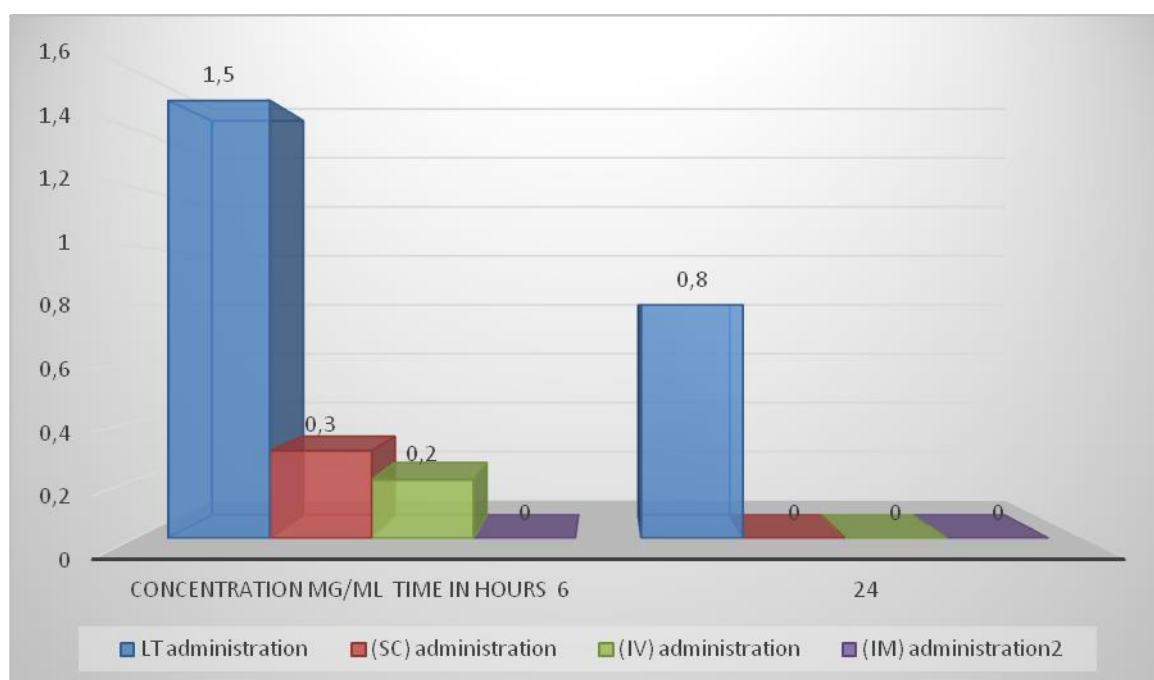


Fig. 2. Dynamics of the concentration of gentamicin in the inguinal lymph node after various methods of antibiotic administration at a dose of 1 mg/kg.

In the soft tissues of the gunshot wound (Fig. 2) after 6 hours with intramuscular and subcutaneous administration, the antibiotic was either not detected or contained in insignificant concentrations. After intravenous administration, the concentration of the antibiotic in soft tissues remained low

(0.12 + 0.06). The lymphotropic method provided higher concentrations in soft tissues and lymph nodes of the limb. And even after 24 hours, with lymphotropic administration, gentamicin was contained in the inguinal lymph nodes and soft tissues of the gunshot wound of the extremity at concentrations ranging from "traces" to 0.87 $\mu\text{g} / \text{g}$, whereas with traditional methods the drug was not detected in the tissues under study.

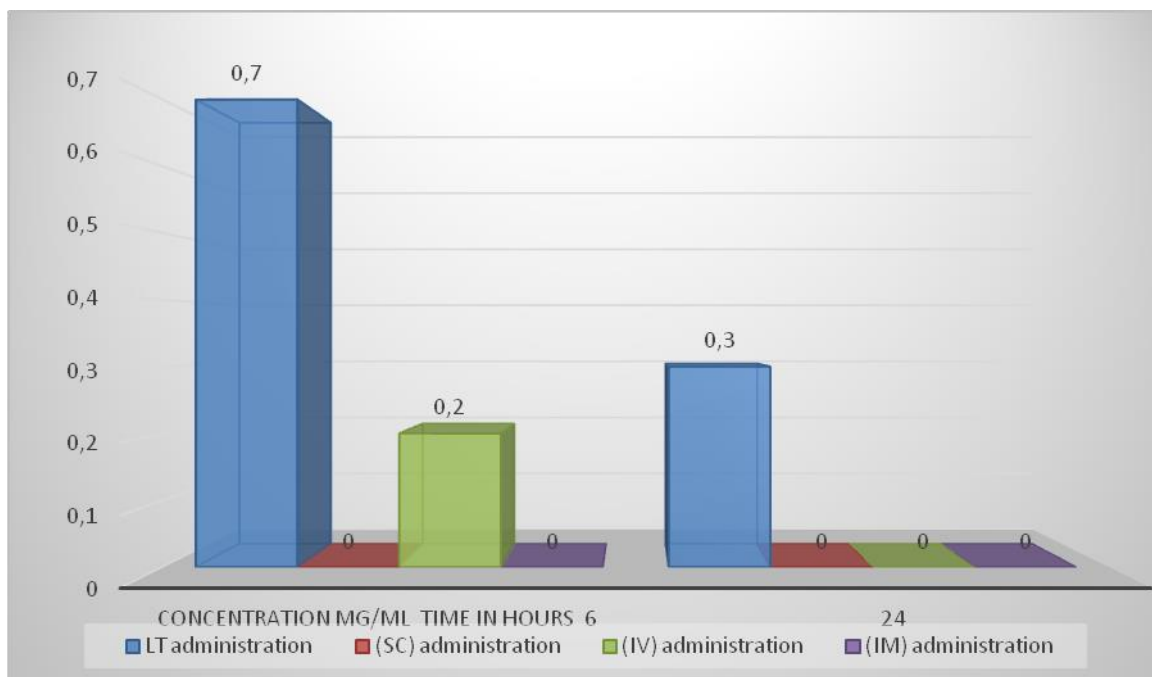


Fig. 3. Dynamics of gentamicin concentration in muscle tissue of a gunshot wound to an extremity after various methods of antibiotic administration at a dose of 1 mg/kg.

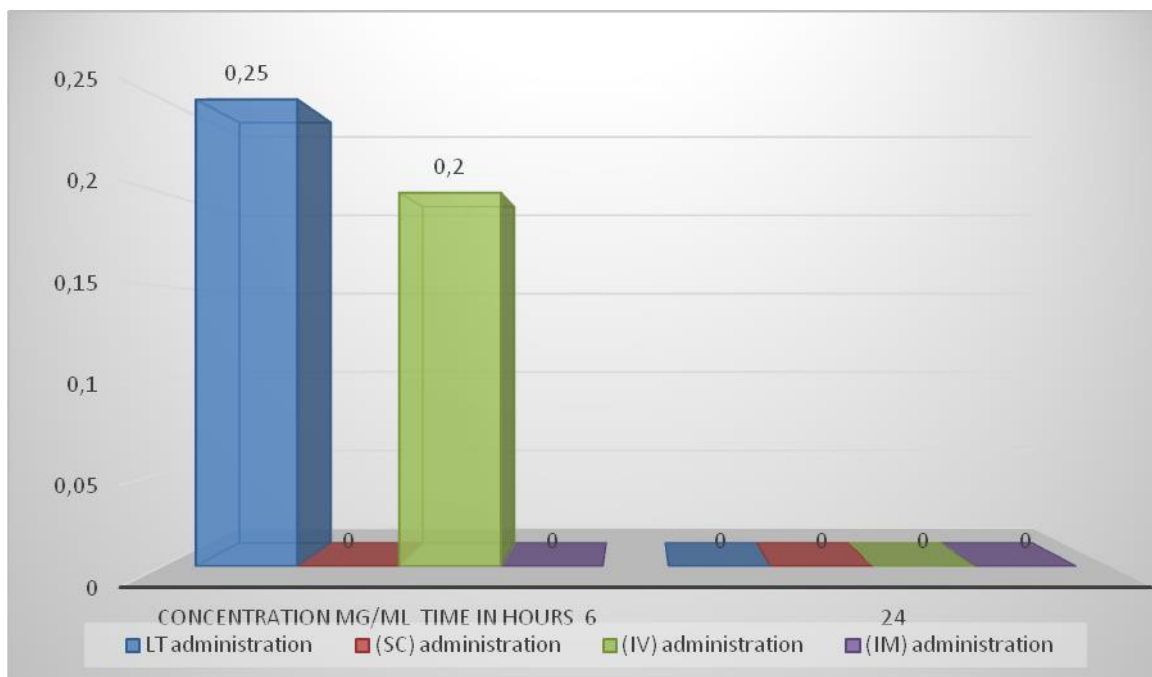


Fig. 4. Dynamics of the concentration of gentamicin in the subcutaneous tissue of a gunshot wound to an extremity after different methods of administration of an antibiotic at a dose of 1 mg/kg.

Thus, experimental studies show that a relatively high and long-term content of gentamicin in the lymph nodes is achieved with the lymphotropic method. The antibiotic introduced by this method is contained in the soft tissues of the gunshot wound of the extremity for a longer time than with traditional methods.

CONCLUSIONS

Lymphotropic antibiotic therapy provides in the blood, lymph nodes, and soft tissues of a gunshot wound a higher and long-lasting level of therapeutic concentration of gentamicin compared to traditional methods of administration, while the daily dose of antibiotics injected and the number of injections are reduced by 2 or more times.

The use of lymphotropic antibiotic therapy and radar, along with surgical treatment of wounds, is an effective method of treating soft tissues of the extremities; it promotes fragmentation and rejection of non-viable tissues, a

rapid decrease in inflammation, and an expansion of indications for the imposition of primary sutures, provides early (5-6 days) autodermoplasty in case of extensive defects.

ACKNOWLEDGMENT

For the first time, the preventive effect and clinical features of the inflammatory process in soft tissues during the use of antibiotics are described. On the basis of experimental and clinical studies, the advantage of lymphotropic antibiotic therapy among other methods of administration of antibiotics has been shown.

The analysis of the tactics and volume of surgical intervention was carried out in case of mass admission of victims with gunshot wounds. The peculiarities of these wounds were revealed, and the tactics of their treatment were assessed. With the massive admission of wounded in an emergency, the actions of a surgeon, traumatologist, and microsurgeon have been developed for gunshot wounds of the extremities. Taking into account the peculiarities of gunshot wounds, modern pathogenetically substantiated methods of regional lymphotropic treatment were used for the first time. The principles of providing EMF in case of mass admission of wounded at the stages of evacuation in the RSCEMP system have been developed.

REFERENCES

1. Abakumov M.M., Berchenko G.N. and others. Gunshot wounds in civilian surgery // Emergency surgery. - M, 1999. - P. 130–134.
2. Abramyan A.V., Teberdiev Yu.B., Grichanovsky A.N. Endolymphatic analgesia // Problems of clinical lymphology and endoecology: Materials. First Russian scientific. Conf. From int. Participation. –M. - Sochi, 1997. - P. 86–87.
3. Avvakumov E.G. Mechanical methods for activating chemical processes: Author's abstract. dis. ... Cand. honey. Sci. - Kuibyshev, 1980. P. 14-26

4. Avtsyn A.P. Essays on military pathology. - M.: Medicine, 1946.
5. Adamyan A.A. The main directions in the development of dressings "Modern approaches to the development of effective dressings and suture materials": Abstracts. Dokl. 1st All-Union Conf. - M, 198. - P.15-16.
6. Adamyan A.A. From the editorial board Modern approaches to the development of effective means, suture materials and polymer implants: Abstracts. Dokl. 3rd Intern. Conf. – M, 1998. P. 154
7. Ado A.D., Ado M.A., Pytskiy V.I. et al. Pathological physiology M. : Triada-X, 2000. P. 521-574
8. Ayvazyan S.A., Bukhstaber V.M., Enyukov I.S., Meshalkin L.D. Applied statistics. Classification and dimension reduction: –M.: Finance and statistics, 1989. P. 339-348. 385-419
9. Alekseev AA, Paltsin AA, Krutikov MG, Kuznetsov VA, et al. Treatment of burn wounds using wound dressings "Activetex" (Manual for doctors). –M., 2000. P. 13
10. Aliev M.Kh., Mamedov Ya.D., Babaeva S.M. A new arsenal of lymphotropic drugs // Ibid. -FROM. P. 66-67.
11. Alisov P.G., Humanenko E.K., Ozeretskovsky L.B. Features of wound ballistics and morphofunctional characteristics of a gunshot musculoskeletal wound // Report on research work on topic No. 2. 2012 P.31-34 "Arsenal" - SPb., 1999. P. 34-38
12. Ankin L.I. and others. Modern methods of treatment of fractures. - Kiev, 1994. P. 250.
13. Ariev T. Ya. Primary treatment of wounds, experience of logical determination // Surgery. –1943. –№7. -FROM. P. 3-9.
14. Ariev T.Ya. Chronic gunshot osteomyelitis: (Pat – anatomy, pathogenesis, clinical picture and treatment): Dr. med. sciences. L., 1948. P. 460-468
15. Ataev A.R. Pathogenetic approaches to the complex treatment of

purulent-inflammatory diseases of soft tissues and gunshot wounds of the extremities: Author's abstract. dis. ... Dr. med. Sciences. - 2003. P.25-31